



**HAL**  
open science

# Cranial Surgery in Antiquity: The Size of Trepanations During the Neolithic Period in France

Emanuela Gualdi-Russo, Pauline Lefebvre, Julie Arnaud

► **To cite this version:**

Emanuela Gualdi-Russo, Pauline Lefebvre, Julie Arnaud. Cranial Surgery in Antiquity: The Size of Trepanations During the Neolithic Period in France. *World Neurosurgery*, 2024, 190, pp.131-140. 10.1016/j.wneu.2024.07.042 . mnhn-04692763

**HAL Id: mnhn-04692763**

**<https://mnhn.hal.science/mnhn-04692763v1>**

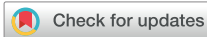Submitted on 10 Sep 2024

**HAL** is a multi-disciplinary open access archive for the deposit and dissemination of scientific research documents, whether they are published or not. The documents may come from teaching and research institutions in France or abroad, or from public or private research centers.

L'archive ouverte pluridisciplinaire **HAL**, est destinée au dépôt et à la diffusion de documents scientifiques de niveau recherche, publiés ou non, émanant des établissements d'enseignement et de recherche français ou étrangers, des laboratoires publics ou privés.



Distributed under a Creative Commons Attribution - NonCommercial - NoDerivatives 4.0  
International License



# Cranial Surgery in Antiquity: The Size of Trepanations During the Neolithic Period in France

Emanuela Gualdi-Russo<sup>1</sup>, Pauline Lefebvre<sup>2</sup>, Julie Arnaud<sup>2,3</sup>

## Key words

- France
- Hole dimensions
- Neolithic
- Neurosurgery
- Trepanation

## Abbreviations and Acronyms

**MNHN:** Muséum National d'Histoire Naturelle

From the <sup>1</sup>Department of Neuroscience and Rehabilitation, University of Ferrara, Ferrara, Italy; <sup>2</sup>Département Homme et Environnement Musée de l'Homme, UMR 7194 – HNH, Paris, France; and <sup>3</sup>Department of Humanities, University of Ferrara, Ferrara, Italy

To whom correspondence should be addressed:  
Emanuela Gualdi-Russo, M.Sc.

[E-mail: [emanuela.gualdi@unife.it](mailto:emanuela.gualdi@unife.it)]

Citation: *World Neurosurg.* (2024) 190:131-140.  
<https://doi.org/10.1016/j.wneu.2024.07.042>

Journal homepage: [www.journals.elsevier.com/world-neurosurgery](http://www.journals.elsevier.com/world-neurosurgery)

Available online: [www.sciencedirect.com](http://www.sciencedirect.com)

1878-8750/© 2024 The Authors. Published by Elsevier Inc.  
This is an open access article under the CC BY license  
(<http://creativecommons.org/licenses/by/4.0/>).

## INTRODUCTION

The term trepanation or trephination refers to a deliberate perforation of the cranial vault *in vivo* with the removal of a portion of skull bone. The former term comes from ancient Greek *τροπανον* meaning trepan, while the latter comes from Latin *tres fines* (three ends) referring to the three-arm drilling tool invented in the 16th century Common Era.<sup>1</sup> “Trepanation” is used more frequently for ancient human remains because it is more generic and does not necessarily refer to the technique used. Practiced since ancient times, this surgery falls squarely within the history of medicine. One of the pioneers of neurology and neurosurgery, founder of modern anthropology, and staunch supporter of head surgery since prehistoric times was Paul Broca. He hypothesized that this surgical practice was applied in the belief that the demons that caused seizures could escape through the cranial holes.<sup>2-4</sup> Beginning with an early case of

The trepanation, a surgical procedure performed on the skull, finds its roots in prehistoric times. This investigation delves into the analysis of the trepanned skulls housed at the Musée de l'Homme in Paris, focusing on those found in France, a region abundant in archaeological evidence of early neurosurgical techniques. With the opportunity to scrutinize these human remains, our study aimed to analyze the dimensions of Neolithic trepanations across 41 skulls. We particularly explored the relationships between minimum and maximum hole diameters, revealing a strong interrelation. Additionally, we successfully applied a straightforward protocol to determine the perforation area in ten Neolithic trepanations. These findings shed light on the medical practices of ancient civilizations, particularly in France during the Neolithic era. Moreover, this study underscores the significance of museum collections as valuable resources for scientific inquiry and the historical understanding of medicine.

trepanation on an Incan skull that had been shown to him by Ephraim George Squier,<sup>5</sup> Broca could confirm the prehistoric practice of trepanation thanks to the discovery in France of hundreds of trepanned skulls—many of them dating back to the Neolithic period.<sup>6,7</sup> Given the numerous cases of trepanned skulls found, Broca suggested that prehistoric cranial surgery existed with 2 different types of operations: 1) operations on the living person as evidenced by the signs of short-term healing (osteoclastic activities around areas of necrotic bone) or long-term healing (extended remodeling and margin rounding); and 2) postmortem operations to produce roundels,<sup>2</sup> as Prunières named these skull fragments because of their generally round shape.<sup>8</sup> Evidence of skull trepanation occurs in many areas of the world, particularly in South America (among others:<sup>9-15</sup>). The earliest evidence dates back to the Mesolithic,<sup>16,17</sup> and then became increasingly frequent in the Neolithic.<sup>13,18</sup> Numerous ancient trepanations show clear traces of healing; sometimes the person drilled survived for a long time, testifying to the operating skills of the surgeon who performed the cranial surgery.<sup>13,19</sup> The practice of trepanation is speculated to have been therapeutic, cultural, or symbolic.<sup>20</sup> Based on current

ethnographic data, both therapeutic and ritual motives are to be considered acceptable.<sup>21</sup> Specifically, theories supporting therapeutic motivation suggest that individuals were subjected to trepanning to relieve intracranial pressure caused by injury or pathology. Cultural theories propose that the trepanation was related to magical-religious motivations or other ethnomedical customs within the community.<sup>19</sup> Of course, a key distinction in motivations for the cranial intervention must be made considering whether it was performed *in vivo* or postmortem, and thus without therapeutic motivation for the person undergoing the procedure.<sup>22</sup> However, in medieval Europe, these roundels/amulets were believed to have healing properties when worn.<sup>23</sup> In any case, the real motivations for the surgical practice in antiquity are difficult to ascertain since the anthropological study of these ancient trepanations has only skeletal evidence available.

In the present study, we proposed an investigation of a sample of trepanned skulls conserved in the Musée de l'Homme in Paris (France) and coming from several geographical and chronological ranges. Within this sample, we intend to give specific attention to the Neolithic subsample from France, which is the most

representative of the whole collection. This is to provide further insight into this practice in prehistoric times and to test a simple protocol to investigate and quantify the extent of the trepanations.

### LESSONS FROM THE MUSEUM COLLECTION

The anthropological collection of the Muséum National d'Histoire Naturelle (MNHN, Paris) stored at the Musée de l'Homme can be useful in making tangible some topics related to trepanation and, at the same time, in examining the general trend of this surgical procedure, taking into account the amount of available human materials, especially from the Neolithic period. The collection of skulls and cranial fragments with the presence of perforations is very large and comes from every part of the world and period (from the Epipaleolithic to the modern age) (Figure 1A).

Among the frequently reported causes for cranial trepanation also accounting for

the higher frequency in the male sex are head wounds from battles,<sup>24,25</sup> as probably attested by the skull features shown in Figures 1B1 and B2.

Nevertheless, several can be the reasons for a cranial hole, from depressions/openings, frequent in the elderly, caused by the thinning of the parietals to pathology (infections, tumors, trauma).<sup>26</sup> In addition, animal activities may also have intervened after the burial of the corpse producing damage. Moreover, defects in ossification can simulate trepanation: in the MNHN collection, we found an interesting case of pseudo-trepanation with holes due to ossification failure (Figure 1C). This developmental defect (enlarged parietal foramina or *Fenestrae parietales symmetricae*) has an autosomal dominant inheritance and is characterized by variable defects in intramembranous ossification of parietal bones. It is a rare genetic disease with a prevalence of 1–9/100,000.<sup>27</sup>

Another specimen of particular interest is the cranial roundels/amulets obtained

by postmortem procedures (Figure 2A and B). Special attention and care were given to the removed disc, such as polishing the margins and, in some exceptional cases, a groove or a hole to facilitate the attachment of a tie so that it could be worn,<sup>7</sup> as shown in Figure 2B. The first reports of roundels obtained by cranial trepanation during the Neolithic date from 1873, with the discoveries of Prunières in the Lozère and de Baye in the Marne. Their interpretation was ritual or therapeutic.<sup>28</sup> In general, their size is within the range of 20–40 mm, although they can reach more than 10 cm.<sup>28</sup>

The trepanations observed in the cranium from the anthropological collection of the MNHN were obtained by different techniques, from scraping to grooving, from drilling to cutting using a sharp instrument (made of stone or iron). Hole features depend on the method used for the trepanation, as given below and in Figure 3.

### Scraping

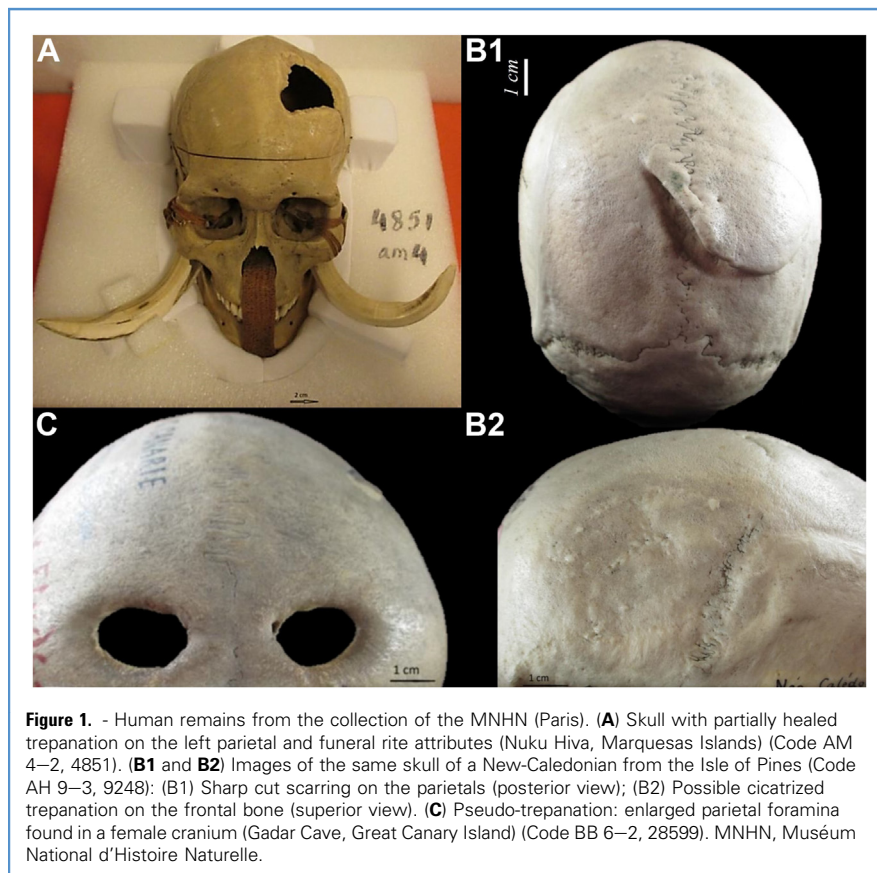
The scraping technique (Figure 3A) involves the gradual abrasion of the outer skull table and diploe with exposure of the inner table, which can be scraped or carefully broken.<sup>26</sup> The tool used was generally lithic, with a flat abrasive surface. Multifaceted stones or advanced tools such as scrapers (raspers) were also employed in this technique.<sup>23</sup> The obtained perforation generally has an ovoid shape with a large abrasion ring around the hole, with external inclination.<sup>29</sup> This is the oldest technique for trepanation and was the most widely practiced in the Neolithic period.<sup>15</sup>

### Grooving

The grooving technique (Figure 3B) involves circumscribing a circular or oval portion of skull bone by repeated cuts with a sharp-tipped stone until a disc of bone can be removed.<sup>26</sup> In practice, the bone is pierced by applying pressure with a sharp instrument that is repeatedly passed back along the groove to the diploe.<sup>30</sup>


### Drilling

This technique (Figure 3C) involves drilling the skull bone with a hard, sharp stone or metal element until a truncated conical hole—the diameter is larger in the outer cranial table than in the inner



**Figure 1.** - Human remains from the collection of the MNHN (Paris). (A) Skull with partially healed trepanation on the left parietal and funeral rite attributes (Nuku Hiva, Marquesas Islands) (Code AM 4–2, 4851). (B1 and B2) Images of the same skull of a New-Caledonian from the Isle of Pines (Code AH 9–3, 9248): (B1) Sharp cut scarring on the parietals (posterior view); (B2) Possible cicatrized trepanation on the frontal bone (superior view). (C) Pseudo-trepanation: enlarged parietal foramina found in a female cranium (Gadar Cave, Great Canary Island) (Code BB 6–2, 28599). MNHN, Muséum National d'Histoire Naturelle.





**Figure 2.** Neolithic skull fragments obtained by trepanation from the Dolmen D'Aiguieres (Lozère, France). **(A)** Neolithic cranial disk (rondel) (Collection of the MNHN, Code AM 2–5, 17360). **(B)** Rondel/amulet of irregular shape with a small hole (in the red circle) to suspend it with a lace (Collection of the MNHN, Code 17357). The first drawing of this rondel from the Prunières collection was published by Broca in 1877 (Finger, Clower, 03). MNHN, Muséum National d'Histoire Naturelle.

**Cranial Trepanations of the MNHN Collection: A General Overview**

The anthropological collection of the MNHN is composed of thousands of human remains, for the main part, stored at the Musée de l'Homme. For storage and accessibility, all the specimens have an inventory number associated with all the information available (among others: location of the finding, chronology, sex, origin of the collected specimen, and pathology). To gather all the available specimens for the present study, we asked the collection managers to extract from the whole database all the specimens presenting a trace of trepanation (attested or suspected). In total, 159 specimens have been subsamples for the present study coming from several geographical areas and chronological ranges.

one—is obtained with a circular contour.<sup>29,31</sup> The cutting edge is clean and without abrasions surrounding the hole, even though grooves or microfractures may be present.<sup>31</sup>

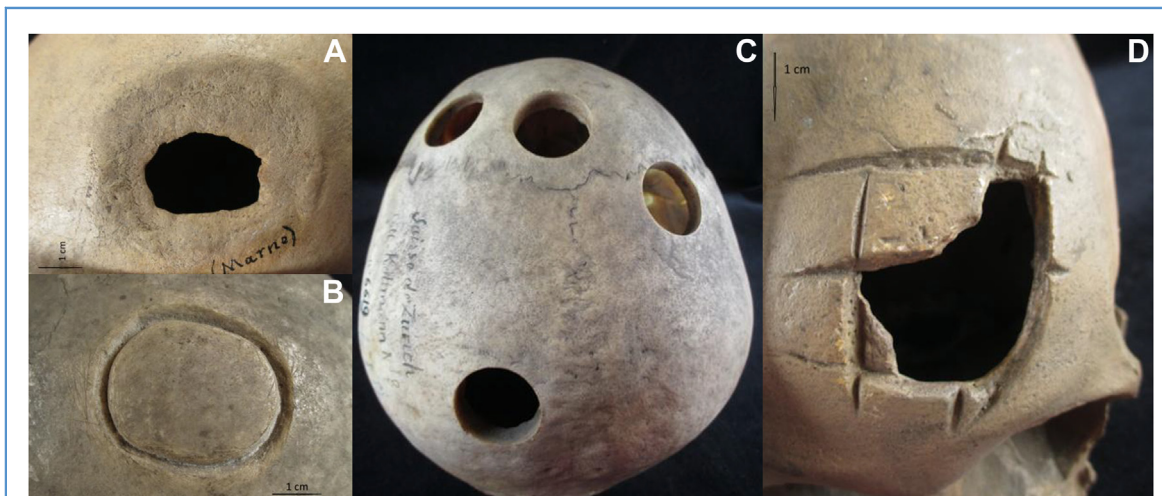**Linear Cutting with Angular Intersection (Rectangular Incisions)**

This technique (Figure 3D) involves 4 straight incisions intersecting at right

angles and the removal of the intermediate fragment.<sup>26</sup> This method, scarcely employed in Europe, has been practiced mainly in South America. This type of trepanation was initially performed with flint, obsidian, or other hard stone knives, and later with metal tools, resulting in various polygonal shapes, mainly rectangular. A curved metal knife (tumi) was used for this purpose in Peru.<sup>32</sup>

A general overview of the characteristics of this sample is given in Table 1.

The most frequently trepanned skull bone is the left parietal followed by the frontal and occipital, while the temporal would be less frequently trepanned. Seventeen percent of the skull fragments were too damaged to determine the exact locations of the trepanation and, for the same reason, the side of the trepanation could not be determined in 14% of cases.



**Figure 3.** Different trepanation techniques: **(A)** Scraping on the left parietal of a skull from the Merovingian period (Aulnizeux, La Vignette, Marne, France; Collection of the Musée de l'Homme, Code AJ 2–1, 23119): lesion with signs of bone healing after trepanation by scraping as evidenced by the characteristic abrasion beveling. **(B)** Incomplete trepanation by grooving on the left parietal (experimentation by Dr. Capitan; Collection of the

Musée de l'Homme, Code AA 7–1, 28815). **(C)** Top view of a skull with 4 drillings performed using a crown of 25.3 mm diameter, 15th century (Bale, Switzerland; Collection of the Musée de l'Homme, Code AB 4–4, 6619). **(D)** Cranial cast with a trepanation by rectangular incision technique (Collection of the Musée de l'Homme, Code BB 5–3, 28590).

**Table 1.** Comparison of Trepanations by Place of Origin, Anatomical Region of the Skull, Side, Sex of Diagnosed Remains, Trepanation Technique, and Presence of Survival Signs

Number of Specimens	Specimen		Locations on the Skull Bones	Skull Side	Surgical Technique (% Survival by Technique)
	Discovery Place (Era)	Sex			
159	45.2% France (Neolithic)	56% males	49.7% parietal	37% left	28.9% scraping (87%)
	4.5% Europe (Middle Ages)	44% females	6.3% occipital	25% midline	57.2% grooving (59.3%)
	11.6% Europe (various)		0.6% temporal	24% right	10.1% drilling (12.5%)
	3.2% Africa (various)		17% ND	14% ND	3.8% rectangular incision (0%)
	0.6% Morocco (Epipaleolithic)				
	2.6% Asia (various)				
	7.7% Oceania (various)				
	13.5% South America (pre-Columbian)				
	0.6% North America (Paleoindian)				
10.3% other					

ND, not determinable fragment.

The highest frequency of trepanned diagnosed individuals was males. The grooving technique was found to be the most frequent; this technique was the most widely used in Europe perhaps due to its greater ease of execution.<sup>23</sup> As for the place of origin, most specimens are obviously from the French territory, where a vast number of cranial remains with trepanations have been found since the late 1800s. In particular, most of these specimens come from the Lozère and Paris Basin regions, starting from the Neolithic and continuing into the Eneolithic and later periods. In the same places, a large number of roundels/amulets obtained by procedures performed *postmortem* were also found in the course of archaeological excavation campaigns.

**Dimensions of Cranial Trepanations in the French Neolithic**

In France, the earliest trepanned skulls recorded are from the early Neolithic

period.<sup>33</sup> This surgical practice seems to intensify in later periods between 3500 and 2000 Before the Common Era. (final Neolithic-Chalcolithic).<sup>34</sup> The human remains from the French Neolithic conserved in the MNHN were found in the late 1800s to early 1900s at sites with collective and multiple burials in a single funerary site (cave or dolmen).<sup>35</sup> These archaeological excavations took place mostly under the direction of Fouju, Lemaire, De Baye, and Prunières, and the human remains with perforation were generally sent to the Anthropology Society in Paris for subsequent study by Broca and Manouvrier.<sup>2,5,36</sup> Figure 4 shows the location of the sites from which the French Neolithic remains preserved in the MNHN originate.

The state of preservation of most of the cranial remains from this collection is relatively poor. However, it has been possible to gather the dimensions of 41 perforations by detecting the minimum

and maximum diameter using a digital caliper. The mean dimensions obtained for each measurement are a minimum of  $29.5 \pm 20.7$  mm and a maximum of  $54.3 \pm 26.1$  mm.

To investigate the relation between the 2 measured diameters of the drilled holes, a linear regression analysis (Figure 5) was performed between the minimum and maximum diameters of each specimen. This analysis, obtained by randomly assuming maximum diameter as the dependent variable and minimum diameter as the independent one, generates the following formula:

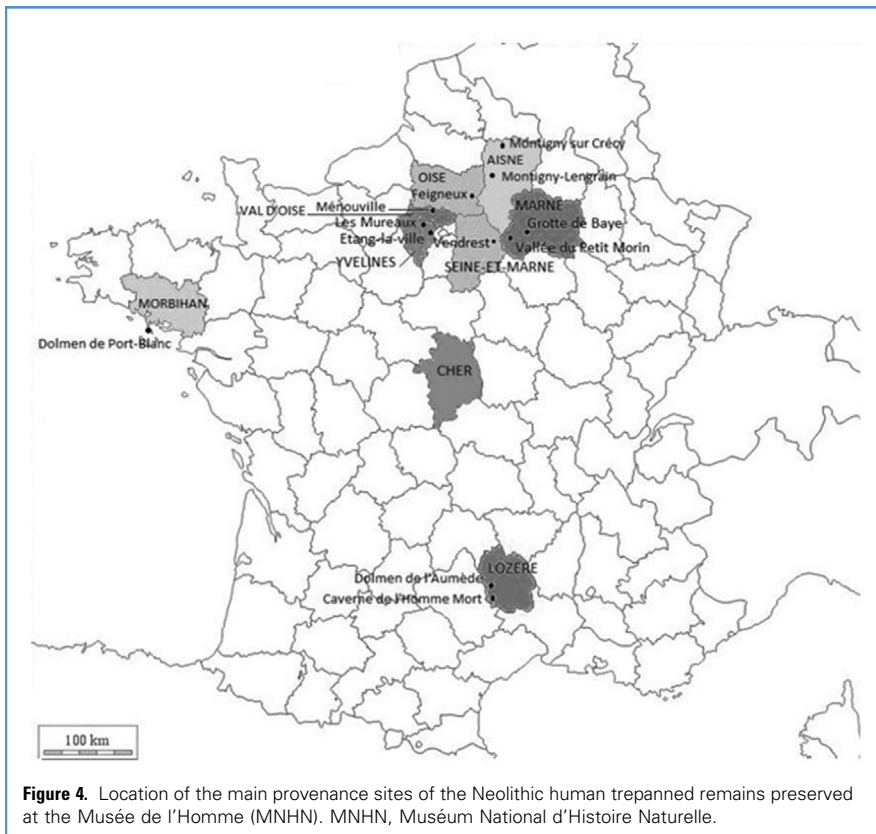
$$\text{Maximum diameter} = 26.5 + 0.9 \times x$$

(where x is the minimum diameter).

The main parameters obtained from the regression analysis are shown in Table 2.

Scatterplot and linear regression analysis (Figure 5) in the selected sample (41 Neolithic trepanations) show that maximum diameter increases as minimum diameter increases (positive linear association). In particular, Table 2 shows the results of the performed simple linear regression analysis displaying the association between the 2 considered diameters of trepanation. According to these results, for every one-unit increase in minimum diameter, there was a corresponding 0.943 mm increase in maximum diameter. The regression model's value of R<sup>2</sup> and P (based on F(1, 39) = 49.293) suggests that the perforation minimum diameter allows the prediction of the other diameter, accounting for 55.8% of the variation in the maximum size of the hole.

Overall, the area of trepanation may be very important because larger trepanations are known to carry a higher risk of survival.<sup>15</sup> Nevertheless, attempts to assess this area are sporadic or absent in the literature.<sup>37</sup> In this context, we selected 10 crania presenting the best-preserved trepanation to quantify the trepanned area. For that, we used photographs in orthogonal projection and the ImageJ open-source software to trace the approximate boundaries of the area,<sup>38</sup> as reported in Figure 6, as an example. The circumference or polygon delimiting the trepanation does not take into account the area of scarring. This technique may also be used to virtually reconstruct the trepanation area even when it is damaged.<sup>37</sup>



The results of the analysis of these 10 Neolithic trepanations are provided in **Table 3**.

**DISCUSSION AND CONCLUSIONS**

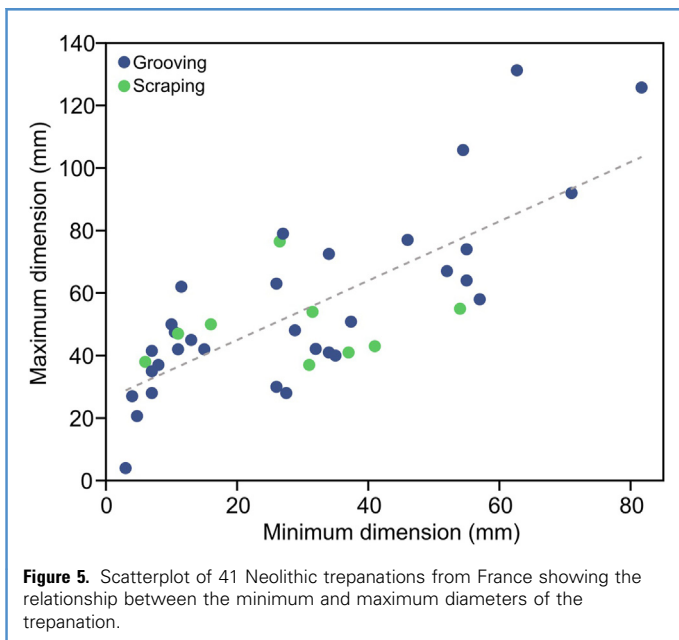
Trepanation is the oldest documented surgical procedure with more than 1500

skulls discovered worldwide.<sup>22</sup> Some of these trepanned skulls show clear signs of healing and others show none. In the latter case, it is not possible to know whether death occurred because of the surgery or because of the worsening of the pathology that had suggested the surgery.

The present study proposed an investigation of trepanations found on skulls or skull fragments on specimens from the Muséum national d'Histoire naturelle de Paris stored at the Musée de l'Homme and dated between 6000 and 2200 years Before the Common Era. In total, 159 specimens from this collection are reported as bearing traces of attested or suspected trepanations. From this collection, it seems that most of the securely sex-determined specimens presenting a trepanation are adult males. This observation is in line with the general trend observed in worldwide trepanations reported up to date.<sup>39,40</sup> The general observation and the analysis of the overall information available for this collection allowed us to obtain a general view of the phenomenon by delving into specific aspects such as the size of cranial trepanation.

France, with some seventy archaeological sites, stands as a primary center for the study of trepanation in the Neolithic. In particular, the greatest concentration of trepanned skulls is from the Lozère, the Languedoc-Roussillon region, and the Paris basin.<sup>41</sup> Outside France, evidence of cranial trepanations dating back to the Neolithic period has also been found, specifically in several other European nations (see among others:<sup>15,19,29,39,42</sup>).

Earlier trepanations generally have round shapes with diameters of 40–50 mm.<sup>43,44</sup> In the present study, the analysis of the French Neolithic trepanations shows a similar trend with mean diameters ranging from about 29 to 54 mm. However, we observed a greater variability, with some trepanations' diameters exceeding 100 mm or falling below 10 mm. Small perforations are believed to result in less blood loss during surgery.<sup>15</sup> These surgeries could be performed quickly, reducing the risk of infection. In addition, the small size of the trepanation results in less pain, especially when performed quickly.<sup>15</sup> An additional important element in avoiding





**Table 2.** Simple Linear Regression Analysis of Trepanation Minimum Diameter on the Maximum One

Variable	B	SE	$\beta$	t	P Value
(Constant)	26.454	4.818		5.490	0.000003
Minimum diameter	0.943	0.134	0.747	7.021	<0.000001
R <sup>2</sup>	0.558				
P	<0.0000001				

B, unstandardized regression coefficient; SE, standard error of B coefficient.

lethal infection was not to nick the dura mater during surgery. In a study of 71 pre-Columbian Incan skulls conducted in Peru, only 22.5% of them showed no evidence of healing.<sup>39</sup> According to other anthropological studies, the evidence of

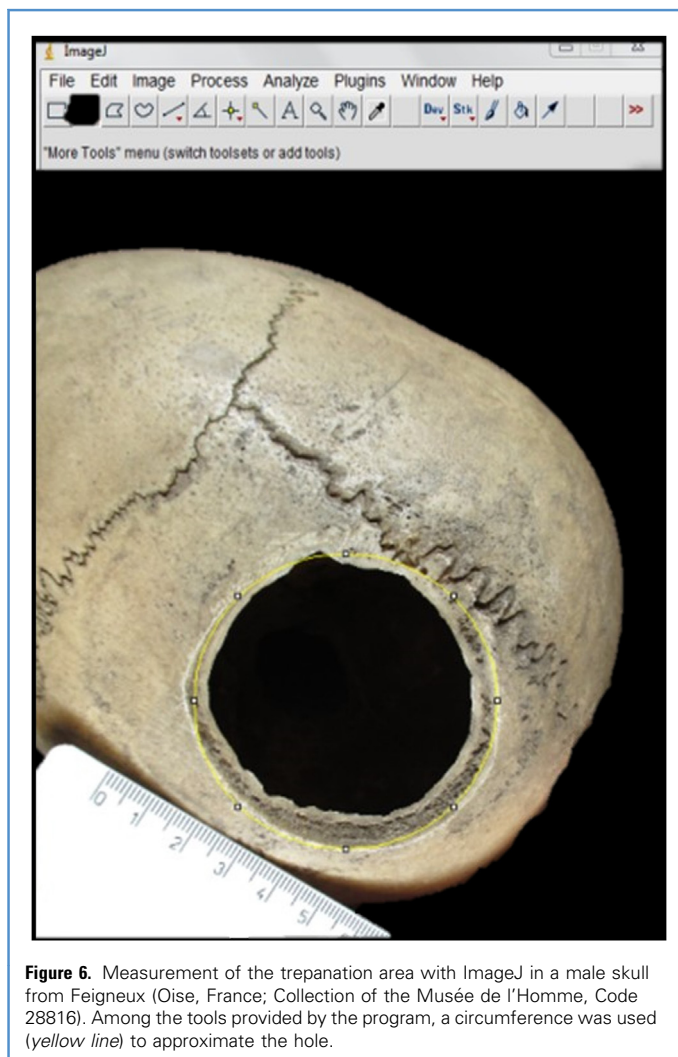healing ranges from 50 to 96% depending on places and times.<sup>37,45-47</sup> Overall, the MNHN specimens from different epochs and places are also included in these percentages with special reference to the scraping and grooving techniques that

would have provided better survival, consistent with previous studies.<sup>39</sup> Scraping especially has emerged as the least invasive technique with the highest chance of survival, as shown in the literature.<sup>37,39</sup>

The results of our study show that the maximum and minimum diameters of the holes are strongly correlated one to the other, meaning that it is possible to predict the dimension of one of the 2 measurements knowing the other. This pattern, evidenced by regression analysis, is certainly largely due to the predominantly circular or oval shape of the holes. This observation and simple methodological approach have the potential to be useful in the future for fragmented specimens to estimate the overall dimension and shape of the drilled holes.

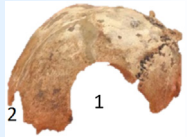

Indeed, the size of the perforation may in turn be an important element in assessing the expertise of these ancient surgeons as well as for patient survival. In addition to the measurement of hole diameters, the application of a simple method of assessing the area of trepanation in Neolithic human remains has proven to be quick and effective. This methodology is especially advisable when the holes have incomplete (fractured) edges or are oblong with an irregular edge since diameters are not sufficient to describe their size.

The MNHN has allowed us to examine, from their collection, the numerous specimens bearing evidence of cranial surgery from all parts of the world, particularly from the French Neolithic period. We believe that this evidence is very important in trying to understand the origin of today's neurosurgery by tracing its earliest steps. It is still debatable and disputed how many of these Neolithic surgeries could have been successfully performed with primitive instruments and without any other pharmacological support, such as anesthetics or antibiotics. To address these deficiencies, the use of sterilized lithic tools and plants with natural analgesic and antibiotic qualities has been hypothesized.<sup>46-50</sup> The high survival rate, despite the danger of cerebral edema, infection, hemorrhage, and shock, is a clear indication of the high level of skill and experience of these early surgeons who performed the trepanation (probably mainly extradural according to<sup>15</sup>).



**Figure 6.** Measurement of the trepanation area with ImageJ in a male skull from Feigneux (Oise, France; Collection of the Musée de l'Homme, Code 28816). Among the tools provided by the program, a circumference was used (yellow line) to approximate the hole.

**Table 3.** Dimensions of the Trepanation Areas Measured on 10 Neolithic French Trepanations

Geographical Location	Site	Code	Lesion Shape	Macroscopic Healing Signs	Main Technique*	Trepanation Area (cm <sup>2</sup> )	Location of the Trepanation Hole	Specimen Type -Conservation Status-	Specimen Image
<i>Ivelines</i> 	Les Mureaux	23304	Oval	X	G	~10	Right side of parietal and occipital bones (1)	Skullcap -Poor-	
			Circular	-	G	~5.1	Left parietal bone (2)		
	L'Etang-la-Ville	30424	Oval	X	S	1.5	Middle of the left parietal bone	Skullcap -Poor-	
<i>Aisne</i> 	Montigny-sur-Crécy	AB-24	Elliptic	-	G	23	Left parietal bone	Cast -Medium-	
			Elliptic	-	G	9.4	Right side of parietal bone and temporal bone.		
	Montigny-Lengrain	24859	Oblong	X	G	29	Along the sagittal suture on both parietal bones and in the upper part of the frontal.	Skullcap -Medium-	

The museum classification code and some descriptive elements of the surgery are given. The red star indicates the region of origin of the specimen in the first column.

\*G, grooving; S, scraping.

Continues



Table 3. Continued

Geographical Location	Site	Code	Lesion Shape	Macroscopic Healing Signs	Main Technique*	Trepanation Area (cm <sup>2</sup> )	Location of the Trepanation Hole	Specimen Type -Conservation Status-	Specimen Image
<i>Oise</i> 	Montigny-Feigneux	28816	Circular	X	G	23.2	Left side of parietal bone along the sagittal suture	Skull -Good-	
<i>Marne</i> 	Baye Cave	24805	Circular	X	S	4.2	Left side of the parietal and frontal bone	Cast -Good-	
	Molincourt	29541	Elliptic	X	S	2.5	Left side of the frontal bone.	Skull -Good-	
<i>Morbihan</i> 	Port-Blanc dolmen	28603	Irregular	X	S	20.8	Left and right sides of parietal bones from the lambda to the middle of both parietal bones.	Skullcap -Poor-	

The museum classification code and some descriptive elements of the surgery are given. The red star indicates the region of origin of the specimen in the first column.

\*G, grooving; S, scraping.

We conclude by pointing out that undoubtedly an important contribution to understanding medicine in antiquity and, in particular, neurosurgery can come from anthropological records. Differential diagnosis, presurgical pathologies, post-operative infection, survival rates, and shape and size of the perforation certainly represent important issues that deserve to be further investigated on ancient human remains characterized by the presence of cranial holes.

### CRedit AUTHORSHIP CONTRIBUTION STATEMENT

**Emanuela Gualdi-Russo:** Conceptualization, Formal analysis, Methodology, Project administration, Software, Supervision, Writing – original draft. **Pauline Lefebvre:** Data curation, Investigation, Writing – review & editing. **Julie Arnaud:** Investigation, Supervision, Visualization, Writing – original draft, Writing – review & editing.

### ACKNOWLEDGMENTS

The authors would like to thank the Muséum National d'Histoire Naturelle for having granted access to the anthropological collection stored at the Musée de l'Homme in Paris together with the responsible and managers of this collection for facilitating access to specimens.

### REFERENCES

- Aidonis A, Papavramidou N, Moraitis K, Papageorgopoulou C. Trepanations in the ancient Greek colony of Akanthos: skull surgery in the light of Hippocratic medicine. *Int J Paleopathol.* 2021;35:8-21.
- Broca P. Sur les trépanations préhistoriques. *Bull Soc Anthropol Paris.* 1876;11:236-256.
- Broca P. Sur la trépanation du crâne et les amulettes crâniennes à l'époque néolithique. Paris: Ernest Leroux; 1877.
- Tsermoulas G, Aidonis A, Flint G. The skull of Chios: trepanation in Hippocratic medicine. *J Neurosurg.* 2014;121:328-332.
- Broca P. Cas singulier de trépanation chez les Incas. *Bull Soc Anthropol.* 1867;2:403-408.
- Fernando HR, Finger S. Ephraim George Squier's Peruvian skull and the discovery of cranial. In: Arnott R, Finger S, Smith CUM, eds. *Trepanation, History- Discovery -Theory.* Lisse: Swets & Zeitlinger; 2003:3-18.
- Finger S, Clower W. On the birth of trepanation. In: Arnott R, Finger S, Smith CUM, eds. *Trepanation, History- Discovery -Theory.* Lisse: Swets & Zeitlinger; 2003:19-42.
- Prunières PB. Sur les crânes artificiellement perforés à l'époque des dolmens. *Bull Soc Anthropol Paris.* 1874;9:185-205.
- Gomez JG. Paleoneurosurgery in Colombia. *J Neurosurg.* 1973;39:585-588.
- Powell BW. Aboriginal trephination: case from southern New England? *Science.* 1970;170:732-734.
- Rifkinson-Mann S. Cranial surgery in ancient Peru. *Neurosurgery.* 1988;23:411-416.
- Velasco-Suarez M, Martinez JB, Oliveros RG, Weinstein PR. Archaeological origins of cranial surgery: trephination in Mexico. *Neurosurgery.* 1992;31:313-319.
- Alt KW, Jeunesse C, Buitrago-Téllez CH, Wächter R, Boës E, Pichler SL. Evidence for stone age cranial surgery. *Nature.* 1997;387:360.
- Mariani-Costantini R, Catalano P, di Gennaro F, di Tota G, Angeletti R. New light on cranial surgery in ancient Rome. *Lancet.* 2000;355:305-307.
- Weber J, Wahl J. Neurosurgical aspects of trepanations from Neolithic times. *Int J Osteoarchaeol.* 2006;16:536-545.
- Dastugue J. Les crânes trépanés de la vallée du Petit-Morin. *Bull mém Soc Anthropol.* 1973;10:249-263.
- Lillie MC. Cranial surgery dates back to Mesolithic. *Nature.* 1998;391:854.
- Capasso L, Michetti E, Pierfelice L, D'Anastasio R. Neurosurgery 7000 years ago in central Italy. *Lancet.* 2002;359:2206.
- Germanà F, Trapanazioni Fornaciari G. *Craniotomie e traumi cranici in Italia dalla Preistoria all'età moderna.* Giardini: PISA; 1992.
- Li H, Xiao X, Huang Y, Zhang H, Lv E, Wang Q. First case of boring-and-cutting trepanation in ancient China. *Archaeol Anthropol Sci.* 2022;14:11.
- Furnas DW, Sheikh MA, van den Hombergh P, Froeling F, Nunda IM. Traditional craniotomies of the Kisii tribe of Kenya. *Ann Plast Surg.* 1985;15:538-556.
- Faria MA. Neolithic trepanation decoded- A unifying hypothesis: has the mystery as to why primitive surgeons performed cranial surgery been solved? *Surg Neurol Int.* 2015;6:72.
- Vovlas A, Di Nunno N, Panzarino G, Sublimi Saponetti S. Cranial trepanation: case studies between the IV century BC and VI century in southern Italy. In: Vovlas A, ed. *Biological Anthropology and case studies.* London, UK: IntechOpen; 2020.
- Han K, Chen X. The archaeological evidence of trepanation in early China. *BIPPA.* 2007;27:22-27.
- Verano JW, Finger S. Chapter 1: ancient trepanation. *Handb Clin Neurol.* 2010;95:3-14.
- Verano JW. Differential diagnosis: trepanation. *Int J Paleopathol.* 2016;14:1-9.
- Orphanet. The portal for rare diseases. Enlarged parietal foramina. Available at: [https://www.orpha.net/consor/cgi-bin/Disease\\_Search.php?data\\_id=10796&lng=en](https://www.orpha.net/consor/cgi-bin/Disease_Search.php?data_id=10796&lng=en). Accessed January 29, 2024.
- Cordier G. Rondelles crâniennes. Une enquête bibliographique. *BSPF.* 2005;102:361-369.
- Giuffra V, Fornaciari G. Trepanation in Italy: a review. *Int J Osteoarchaeol.* 2017;27:745-767.
- Aufderheide AC, Rodríguez-Martin C, Langsjoen O. *The Cambridge encyclopedia of human paleopathology.* 478. Cambridge: Cambridge University Press; 1998.
- González-Darder JM. La trepanación craneal en las culturas primitivas [Cranial trepanation in primitive cultures]. *Neurocirugía.* 2017;28:28-40.
- Gross CG. A hole in the head. *Neuroscientist.* 1999;5:263-269.
- Beyneix A. Mourir au Néolithique ancien en France méditerranéenne. *L'Anthropologie.* 2008;112:641-660.
- Beyneix A. La médecine au Néolithique. *Archeologia.* 2013;506:52-60.
- Masset C. *Les dolmens, sociétés néolithiques et pratiques funéraires.* Paris: Errance; 1997.
- Manouvrier L. Deux trépanations crâniennes avec longue survie et déformations consécutives. *Bull Soc Anthropol Paris.* 1903;4:404-417.
- Arena F, Larocca F, Gualdi-Russo E. Cranial surgery in Italy during the bronze age. *World Neurosurg.* 2022;157:36-44.
- Schneider CA, Rasband WS, Eliceiri KW. NIH Image to ImageJ: 25 years of image analysis. *Nat Methods.* 2012;9:671-675.
- Erdal YS, Erdal OD. A review of trepanations in anatolia with New cases. *Int J Osteoarchaeol.* 2011;21:505-534.
- Kurin DS. Trepanation in South-Central Peru during the early late intermediate period (ca.AD 1000-1250). *Am J Phys Anthropol.* 2013;152:484-494.
- Chauvet D, Sainte-Rose C, Boch AL. Le mystère des trépanations préhistoriques: la neurochirurgie serait-elle le plus vieux métier du monde ? [The mystery of prehistoric trepanations: Is neurosurgery the world eldest profession?]. *Neurochirurgie.* 2010;56:420-425.
- Holck P. Two medieval 'trepanations': therapy or swindle? *Int J Osteoarchaeol.* 2008;18:188-194.
- Campillo D. Neurosurgical pathology in prehistory. *Acta Neurochir (Wien).* 1984;70:275-290.
- Stone JL, Miles ML. Skull trepanation among the early Indians of Canada and the United States. *Neurosurgery.* 1990;26:1015-1020.

45. Aufderheide AC. The enigma of ancient cranial trepanation. *Minn Med.* 1985;68:119-122.
46. Gerszten PC, Gerszten E, Allison MJ. Diseases of the skull in pre-Columbian South American mummies. *Neurosurgery.* 1998;42:1145-1152.
47. Díaz-Navarro S, Tejedor-Rodríguez C, Arcusa-Magallón H, et al. The first otologic surgery in a skull from El Pendón site (Reinoso, Northern Spain). *Sci Rep.* 2022;12:2537.
48. Manouvrier L. Incisions, cauterisations et trepanations crâniennes de l'époque néolithique. *Bull Mem Soc Anthropol Paris.* 1904;5:67-73.
49. Piek J, Lidke G, Terberger T, Smekal U, Gaab MR. Stone age skull surgery in Mecklenburg – vorpommern: A systematic study. *Neurosurgery.* 1999; 45:147-151.
50. Merlin MD. Archaeological evidence of the tradition of psychoactive plant use in the old world. *Econ Bot.* 2003;57:295-323.

*Conflict of interest statement: The authors declare that the article content was composed in the absence of any commercial or financial relationships that could be construed as a potential conflict of interest.*

Received 6 April 2024; accepted 4 July 2024

Citation: *World Neurosurg.* (2024) 190:131-140.  
<https://doi.org/10.1016/j.wneu.2024.07.042>

Journal homepage: [www.journals.elsevier.com/world-neurosurgery](http://www.journals.elsevier.com/world-neurosurgery)

Available online: [www.sciencedirect.com](http://www.sciencedirect.com)

1878-8750/© 2024 The Authors. Published by Elsevier Inc.

This is an open access article under the CC BY license (<http://creativecommons.org/licenses/by/4.0/>).